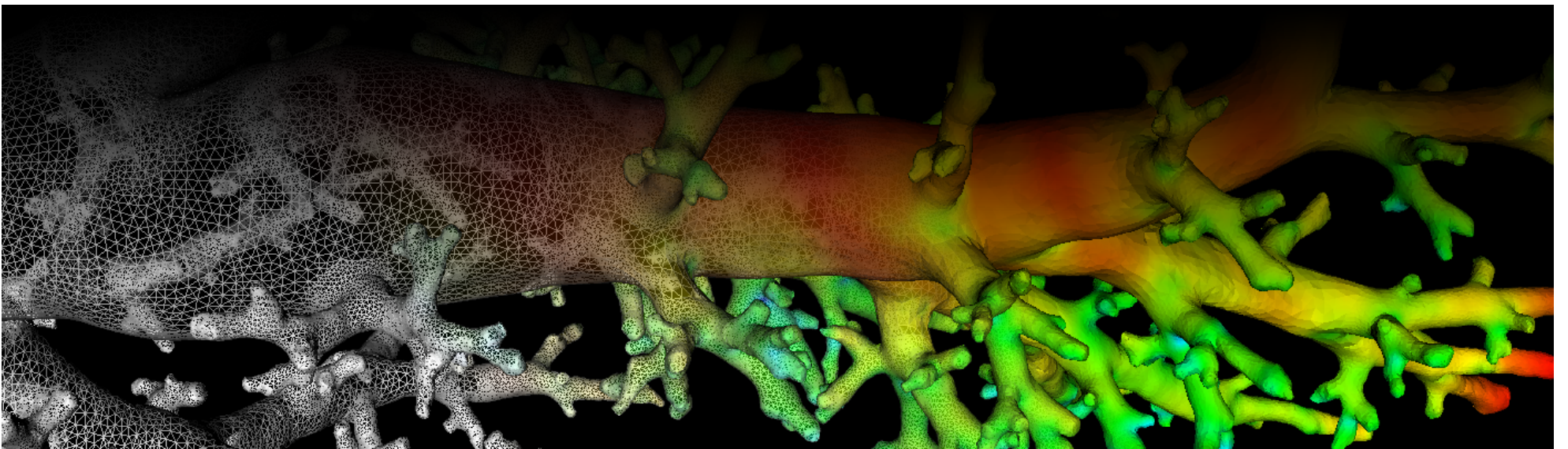
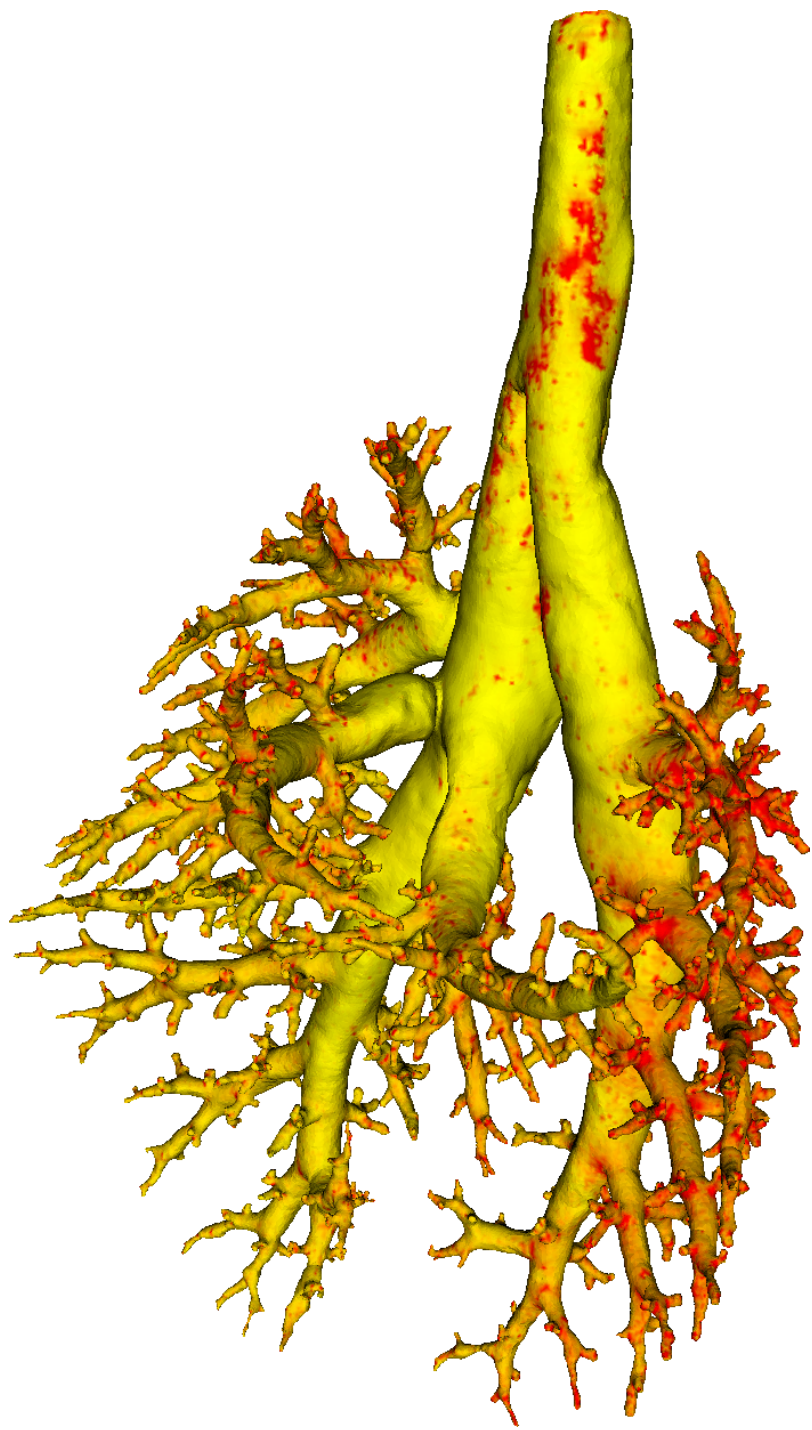


# Lung Anatomy + Particle Deposition (lapd) Mouse Archive for Modeling and Computational Toxicology



m05

[Go to data folder](#)



## Mouse Physiologic Parameters

- Sex: Male
- Strain: CD-1
- Weight (g): unknown
- Vendor: Charles Rivers
- Physical abnormalities: none
- Protocol (<https://cebs-ext.niehs.nih.gov/cahs/file/lapd/pages/Core/Animal%20Model.pdf>)

## Aerosol Dosing

- Particle size: 1 micron
- Exposure time: 10 minutes
- Exposure estimate: 3.19E+08 FMS

Time	RR (bpm)	Vt (ml)	VE (ml/min)	I:E
Pre Aerosol	125	0.31	39.1	0.85
Post 5 Aerosol	122	0.28	33.8	0.68
Post 10 Aerosol	123	0.31	37.7	0.71

## Slicing Info

- Approximate lung orientation: LAS
- Camera: D7100, 14-bit, 200mm Nikkor Macro lens, f/16
- Voxel size: 4.56 x 4.56 x 9.52 (microns)

- Image exposures (msec). ISO=160, all images.

	mt	ol	fl	rd	Notes
excitation	UVND2	UVND2	485/20	560/20	center wavelength/fwhm
emission	N/A	470/30	535/30	635/30	(nm)
Image	Exp	Exp	Exp	Exp	Notes
white	12.5	76.9	5000	125	rhodamine b in OCT
cal	12.5	50	40	200	
images	N/A	40	13000	250	
darks		40	13000	250	

- Notes regarding slicing:
  - The lung was twisted in the OCT.
  - The left lung may have gone slightly out of the field of view.
  - The right lung touched one of the fiducial markers.
  - Lung "tips" are very bright.

## Airway Segmentation

- Total centerline length: 569.515 mm
- Number of branches: 1348
- Number of terminal branches: 675
- Maximum generation number: 23
- Number of outlet areas: 1709

## Compartment Sizes and Aerosol Deposition

- Lung volume: 1211.21 (mm<sup>3</sup>)

Compartments	Count	Volume (mm <sup>3</sup> )
Lung	1	1211.21
Lobes	5	242.24±109.87
Sublobes	55	21.23±21.90
Near acini	465	2.43±1.33

Lobe	Volume (mm <sup>3</sup> )	Average aerosol deposition
left	400.16	1.57±1.55
cranial	233.10	1.28±1.21
middle	150.64	0.94±0.86
caudal	326.14	0.80±0.74
accessory	101.17	1.12±1.00

## Additional Notes

- Overall quality: B
- Lung tissue in part of left lobe looked unusual
- Small tip of accessory lobe is included in cranial lobe segmentation
- Cryomicrotome stoppage lead to imaging artifacts and some missing airway branches

Updated: 7/24/19  
2018 r2b